



Immediate Placement and Loading of MultiNeO™ Implant with Nano Hydrophilic Surface NiNA™ in Anterior Mandible

Dr. Stuardo Valenzuela Manfredi | 🇨🇱 Chile

🕒 CASE DESCRIPTION

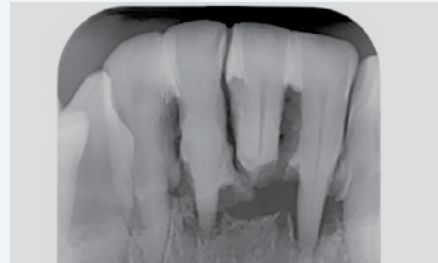
65 year old patient, with controlled diabetes mellitus, arrived at the clinic suffering from teeth mobility and pain upon chewing in the lower incisor area.

A CBCT and a digital impression were taken prior to extraction of the lower incisors.

After the extraction, two MultiNeO Implants with Nano Hydrophilic Surface NiNA, D3.2 x L13 mm, were immediately installed.

Immediate loading of healing abutments and augmentation of hard & soft tissues, were performed on the day of surgery.

1 | INITIAL SITUATION

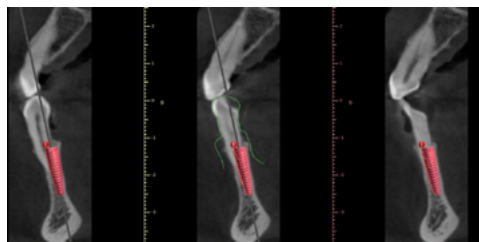
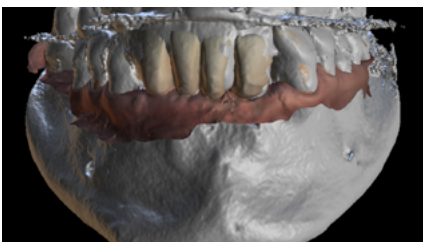


• Pre-op Xray

2 | TREATMENT

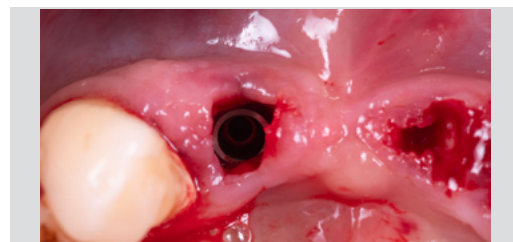
- Temporary immediate loading, with augmentation of hard & soft tissues in the same surgery.

3 | DIGITAL PLANNING

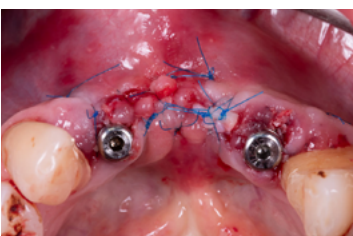


• Digital planning

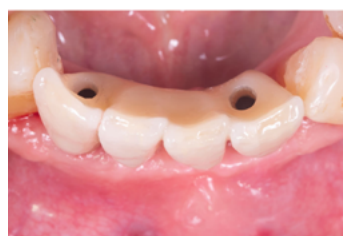4 | SURGERY



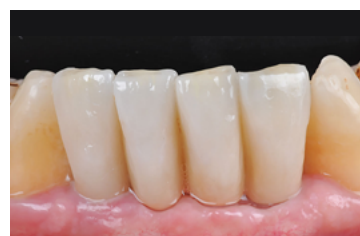• Implant in place following extraction and bone grafting



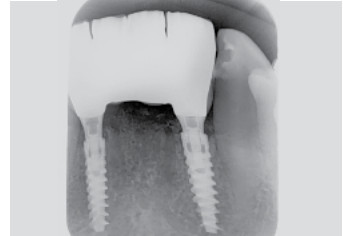• Situation following connective tissue graft



• Final restoration: A screw retained zirconia bridge attached to non-engaged Ti-bases was placed 3 months post-op.



• Final restoration



• X-ray with final restoration



PRODUCT IN USE

Ø 3.2 L13 MM

MULTINEO™

NiNA™
Nano Hydrophilic Surface

